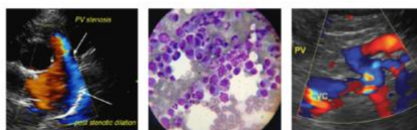


IMAGING PERFORMED BY

SVS Mobile Imaging CT 262-366-5970
fredgromalak@gmail.com



Clinical Sonography & Telectology

EDUCATIONAL TELECONSULTATION SERVICES™

1-800-838-4268 info@sonopath.com SonoPath.com

PATIENT

Mal Markowski

SPECIES

Canine

BREED

Mixed breed

SEX

FS

AGE

13 years

WEIGHT

24.3 kg

INTERPRETED BY

Remo Lobetti, BVSc,
MMedVet (Med), PhD, Dipl.
ECVIM

IMAGING PERFORMED BY

Tom McNeill

HOSPITAL NAME

SVS Imaging CT

REFERRING VET

WVRC – Dr Wirth

INVOICE

303064

DATE

6/25/22

PRESENTING CLINICAL SIGNS

History: Abdominal distention. Previous cystotomy for uroliths – on dissolution diet.

Physical Examination: N/A.

Urinalysis: N/A.

CBC: N/A.

Serum Biochemistry: Elevated ALP activity.

Radiographic Findings: N/A.

ULTRASONOGRAPHIC EXAMINATION OF THE ABDOMEN**Urinary System**

Full urinary bladder with a thickened (0.62 cm) and irregular appearance of especially the apical wall. Moderate amount of floating hyperechogenic sediment. Two uroliths evident (1.1 and 1.4 cm)

Normal trigone area, proximal urethra, and iliac blood vessels.

Normal iliac lymph nodes. Ureters not visualized.

Normal renal size (both 6.1 cm) with increased echogenic appearance, some loss of cortico-medullary differentiation, and normal pelvis and capsule. Small hypoechogenic cortical nodule (0.3 cm) in caudal pole of the right kidney.

Reproductive System

N/A.

Adrenal Glands

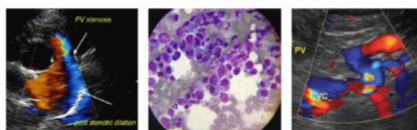
Normal shape, echogenic appearance, size, and position. Left 0.53/0.67 cm, right 0.64/0.55 cm.

Spleen

Normal size and echogenic appearance. Smooth homogenous parenchyma, smooth curvi-linear capsule, and normal vasculature. No evidence of inflammatory, neoplastic, infarction, or infiltrative changes noted.

Liver

Normal size with a diffuse hyperechogenic and nodular appearance, and some loss of portal markings. Nodules are irregular, hypoechogenic, and parenchymal and up to 0.7 cm in size. Focal hyperechogenic nodule (1.1 x 1.7 cm) in the left lobe with a hypoechogenic appearance of the surrounding parenchyma. Full gall bladder containing normal anechoic bile. Normal thickness and echogenic appearance of the gall bladder wall. Normal bile duct.

**PATIENT*****Gastrointestinal***

Mal Markowski

Normal appearance of the stomach, duodenum, small intestine, ileo-cecal junction, and colon with no loss of layering, normal wall thickness (stomach 0.36 cm, duodenum 0.43 cm, jejunum 0.4 cm, colon 0.18 cm) and peristaltic activity, and no distension of the lumen.

SPECIES

Canine

Pancreas

Normal size and echogenic appearance. Normal echogenic appearance of the mesentery and fat surrounding the pancreas.

BREED

Mixed breed

Free Abdomen**SEX**

Normal mesenteric lymph nodes (0.8 x 2.4 cm).
No ascites.

FS

AGE

13 years

ULTRASONOGRAPHIC FINDINGS

Primary Findings:

- Thickened urinary bladder wall.
- Urine sediment and uroliths.
- Nodular hepatopathy.

WEIGHT

24.3 kg

Secondary Findings:

- Renal nodule.
- Age-related renal changes.

INTERPRETED BYRemo Lobetti, BVSc,
MMedVet (Med), PhD, Dipl.
ECVIM**INTERPRETATION OF THE FINDINGS & FURTHER RECOMMENDATIONS****IMAGING PERFORMED BY**

Tom McNeill

The most likely etiology for the thickened urinary bladder wall would be secondary to the uroliths with cystitis and emerging neoplasia, differential diagnoses.

HOSPITAL NAME

SVS Imaging CT

Etiologies for the liver would be hyperplasia, nodular regeneration, granulomatous disease, chronic hepatitis, and neoplasia. Etiologies for the focal nodule would be large regenerative nodule, granuloma, and neoplasia.

REFERRING VET

WVRC – Dr Wirth

The renal nodule is most likely an incidental finding but emerging neoplasia needs to be considered and regularly monitored.

Further assessment would be urinalysis, urine culture, BRAF assay, and FNA cytology of the liver and the hyperechogenic nodule. Tru-Cut/wedge biopsy of the liver may, however, be required for a final etiological diagnosis. Cystomy to remove the uroliths and biopsy the bladder wall should also be considered, which would also allow for a wedge biopsy of the liver.

INVOICE

303064

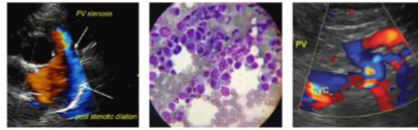
Specific therapy would be dependent on an etiological diagnosis. Symptomatic management of the liver would be ursodiol.

DATE

6/25/22

IMAGING PERFORMED BY

SVS Mobile Imaging CT 262-366-5970
fredgromalak@gmail.com



Clinical Sonography & Telectology

EDUCATIONAL TELECONSULTATION SERVICES™

1-800-838-4268 info@sonopath.com SonoPath.com

PATIENT

Mal Markowski

SPECIES

Canine

BREED

Mixed breed

SEX

FS

AGE

13 years

WEIGHT

24.3 kg

INTERPRETED BY

Remo Lobetti, BVSc,
MMedVet (Med), PhD, Dipl.
ECVIM

IMAGING PERFORMED BY

Tom McNeill

HOSPITAL NAME

SVS Imaging CT

REFERRING VET

WVRC – Dr Wirth

INVOICE

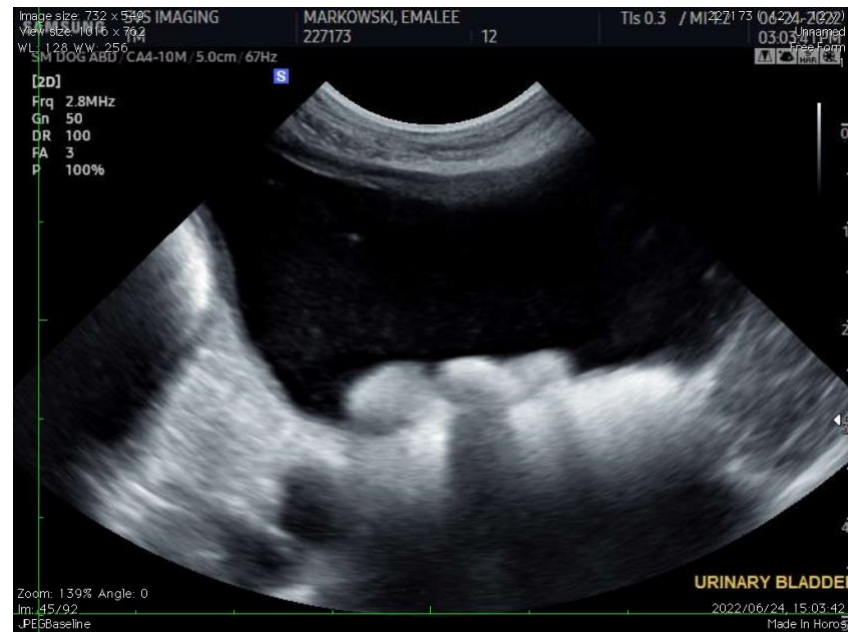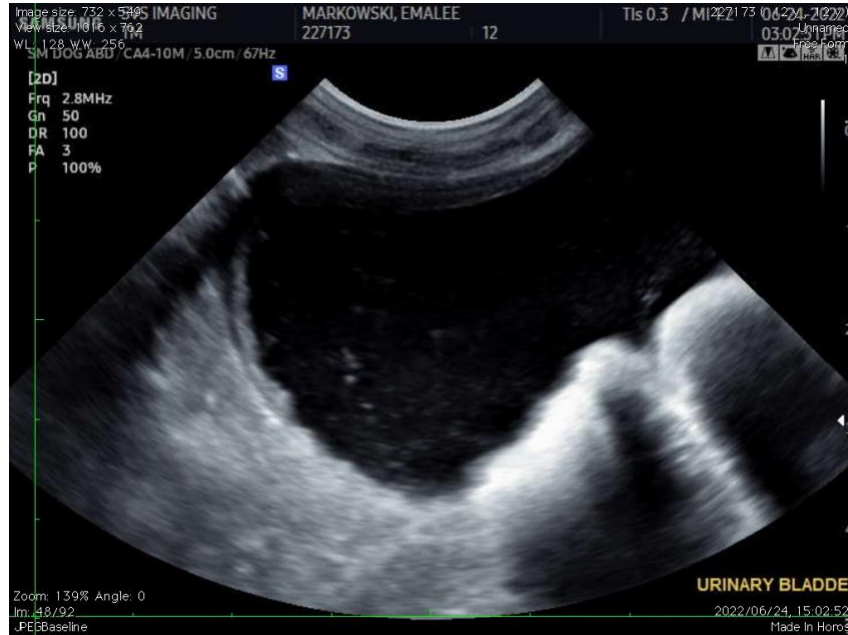303064

DATE

6/25/22

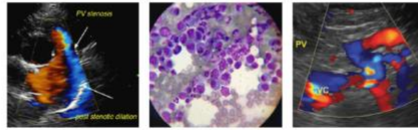
IMAGES

Urinary bladder



IMAGING PERFORMED BY

SVS Mobile Imaging CT 262-366-5970
fredgromalak@gmail.com



Clinical Sonography & Telectology

EDUCATIONAL TELECONSULTATION SERVICES™

1-800-838-4268 info@sonopath.com SonoPath.com

PATIENT

Liver

Mal Markowski

SPECIES

Canine

BREED

Mixed breed

SEX

FS

AGE

13 years

WEIGHT

24.3 kg

INTERPRETED BY

Remo Lobetti, BVSc,
MMedVet (Med), PhD, Dipl.
ECVIM

IMAGING PERFORMED BY

Tom McNeill

HOSPITAL NAME

SVS Imaging CT

REFERRING VET

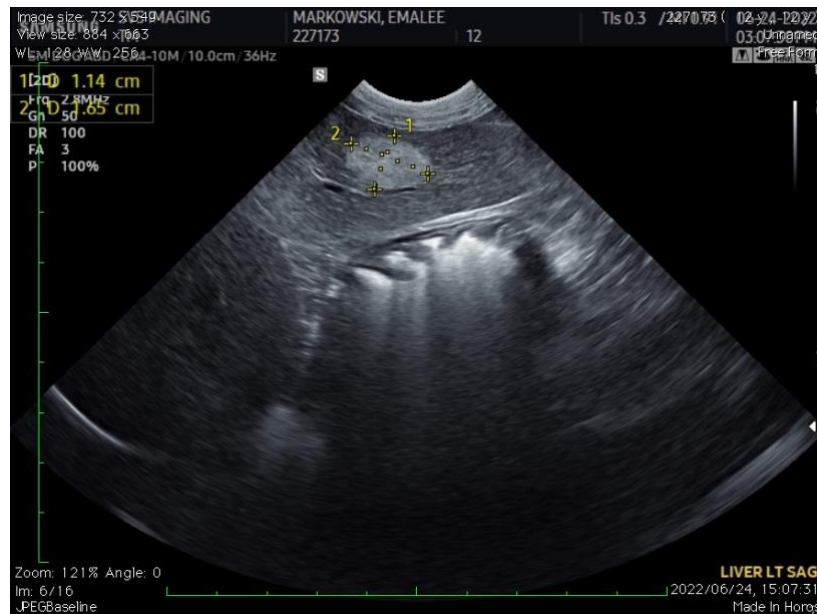
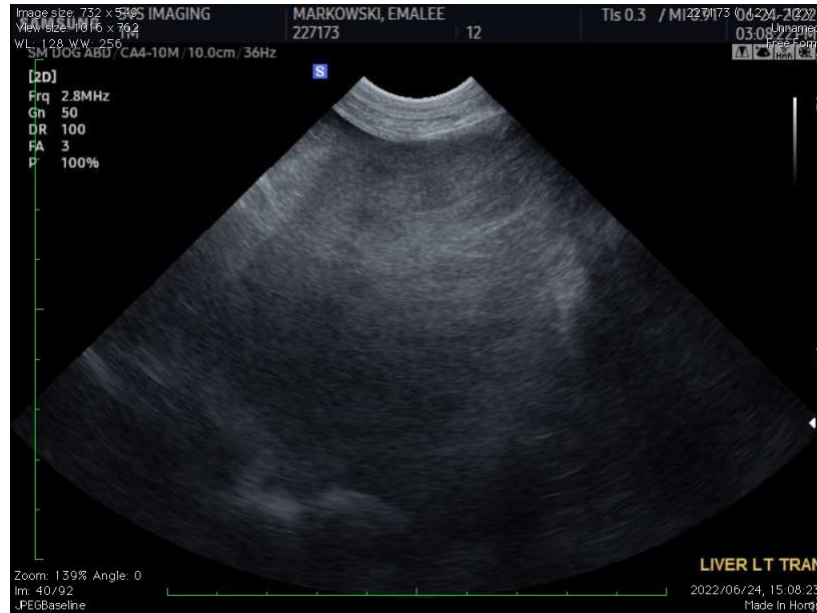WVRC – Dr Wirth

INVOICE

303064

DATE

6/25/22



The information and recommendations provided are based on the images presented by the referring veterinarian. No evaluation can be communicated regarding pathology that was not visible in the image/video clips provided.

Thank you for this referral. If the clinical or image interpretation does not parallel your findings or if I can be of any further assistance, please contact me.

Remo Lobetti, BVSc, MMedVet (Med), PhD, Dipl. ECVIM (Internal Medicine)
rlobetti@mweb.co.za